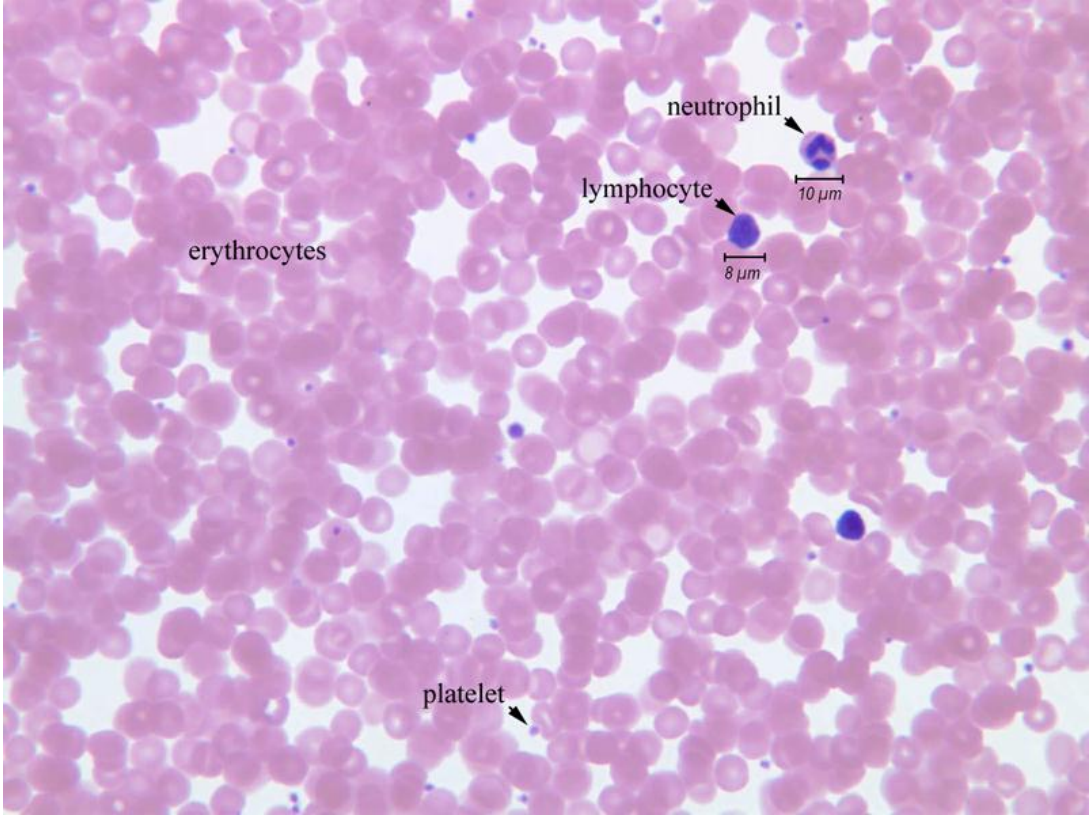
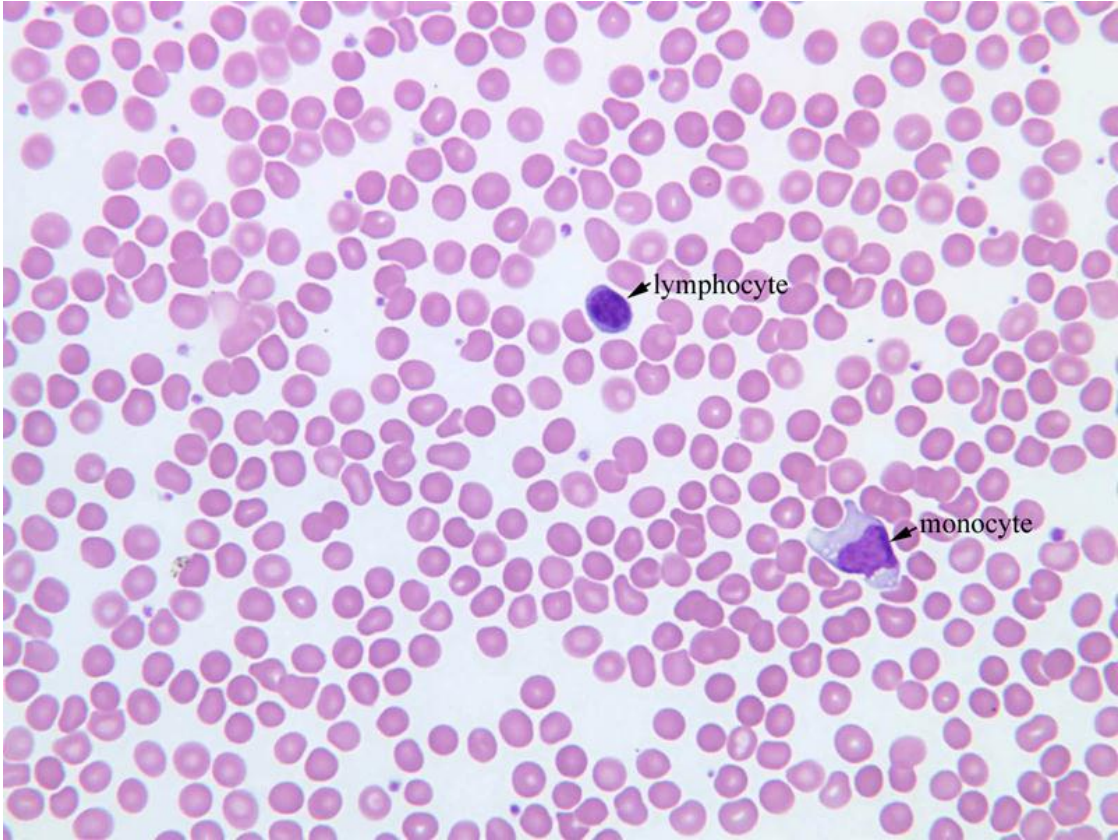


**NORMAL HUMAN BLOOD SMEAR**

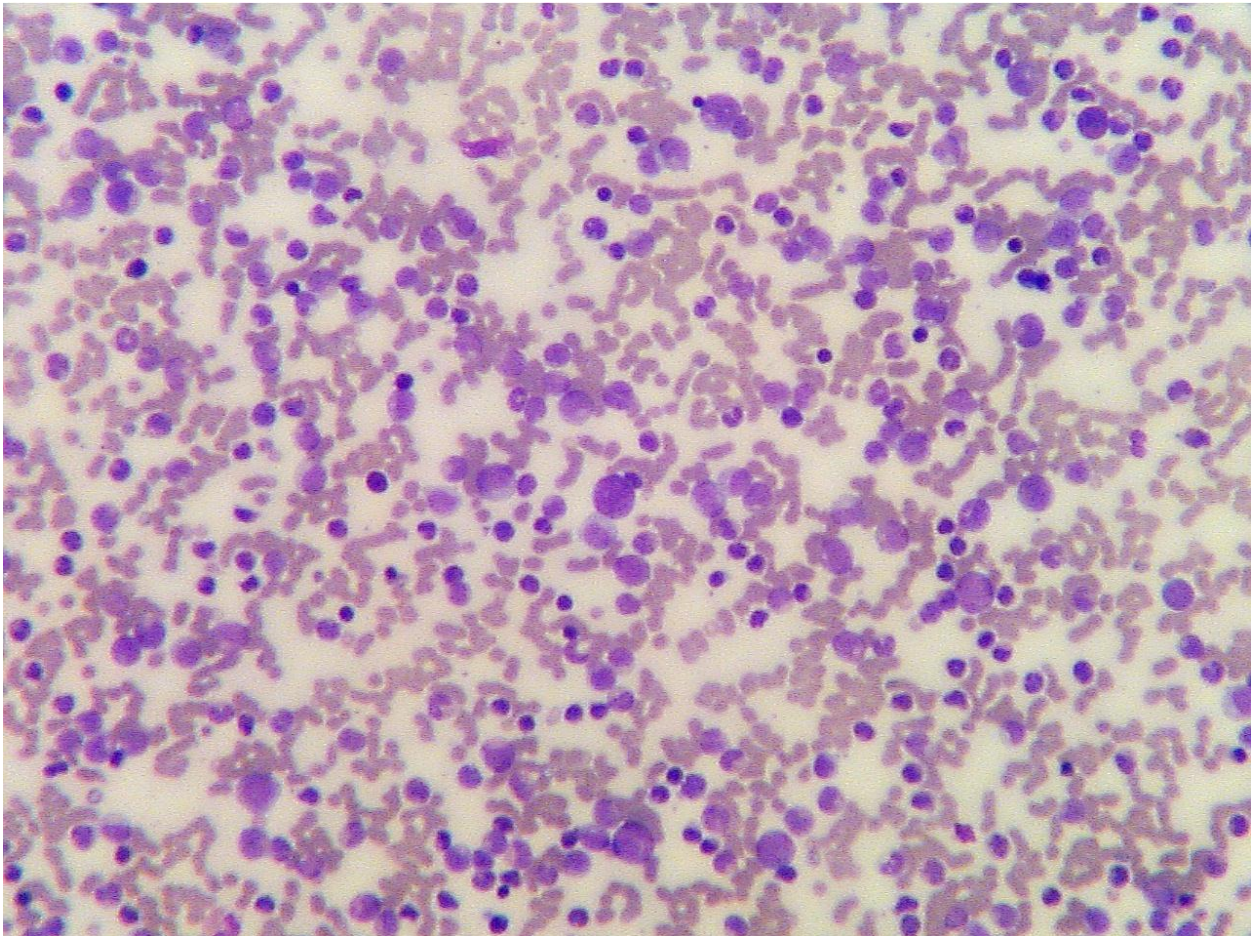
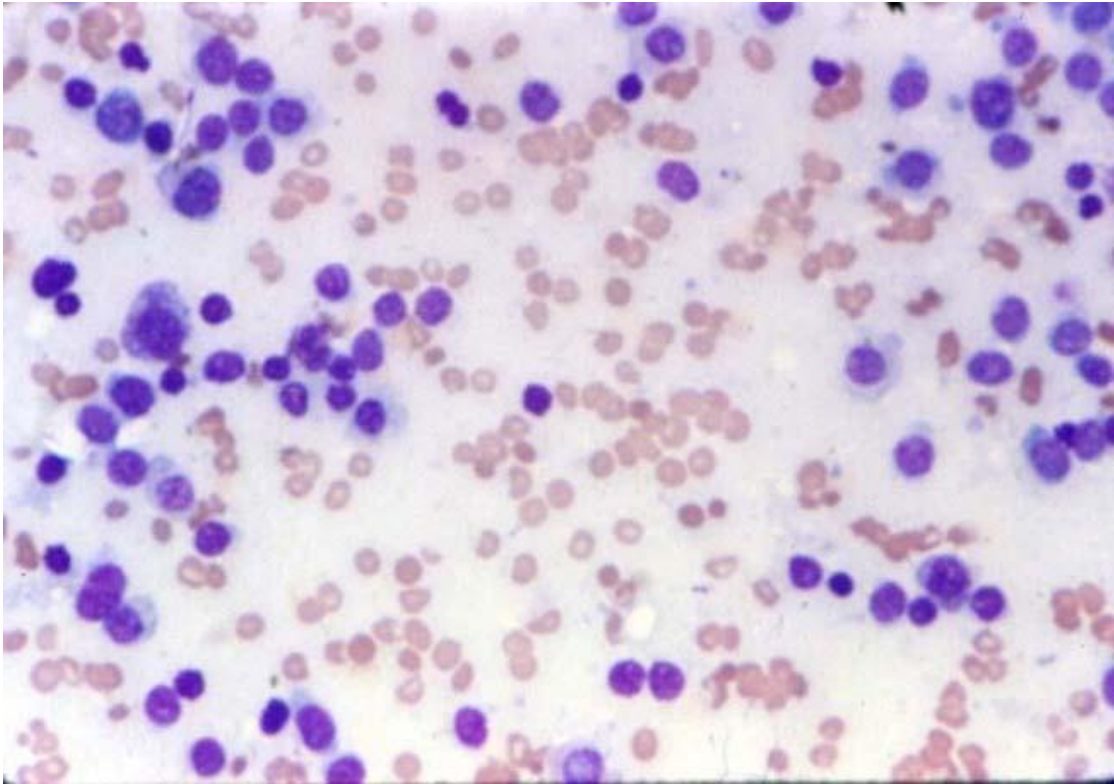


**NORMAL BLOOD SMEAR WITH MONOCYTE AND LYMPHOCYTE**

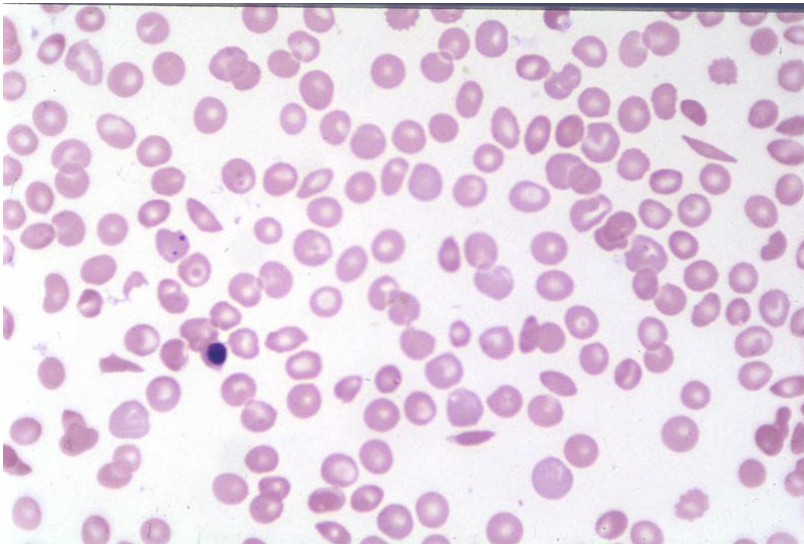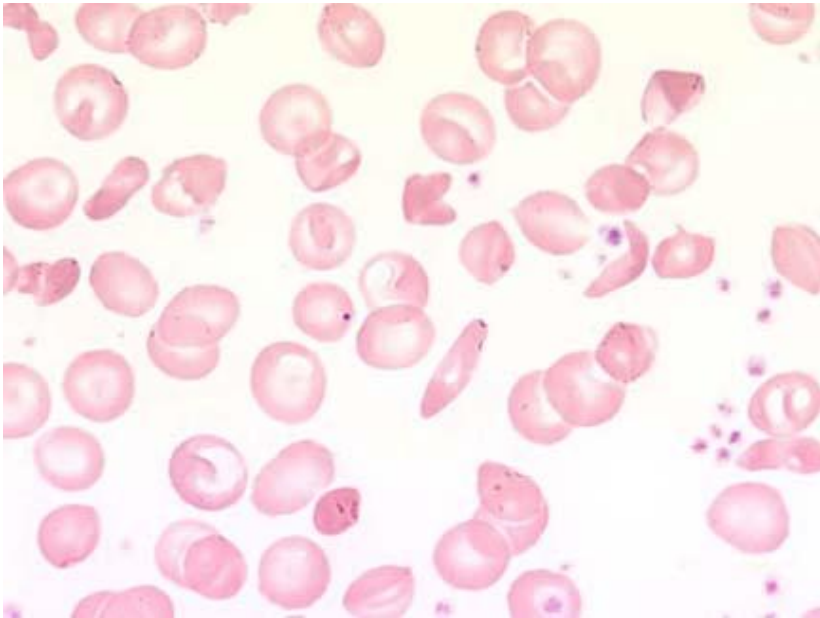
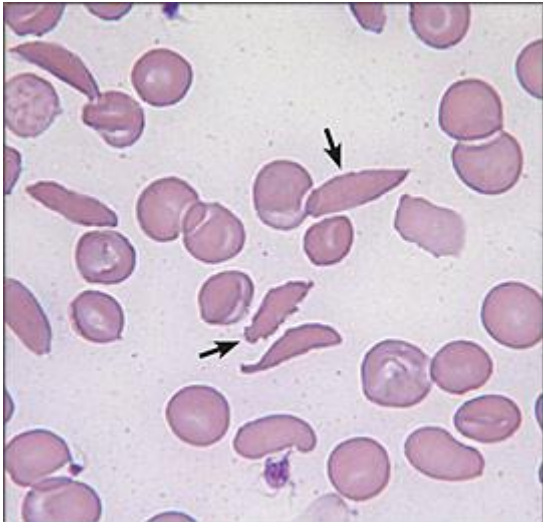




CHRONIC LYMPHATIC LEUKEMIA



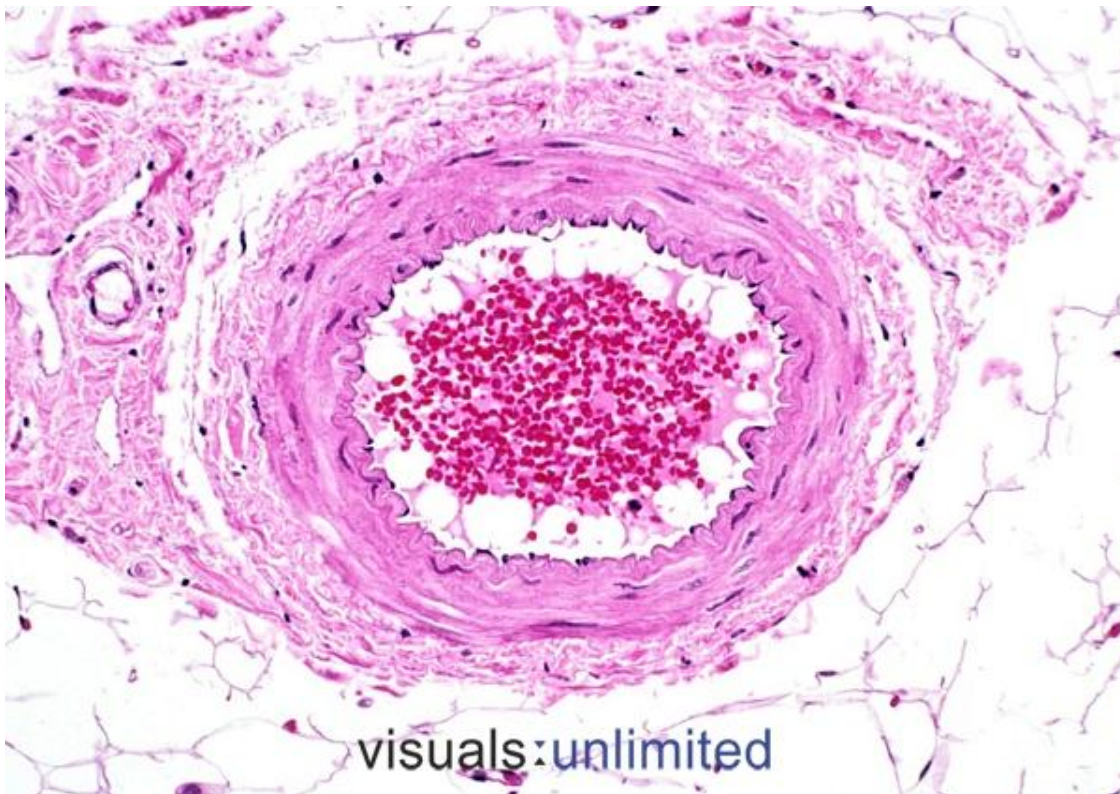
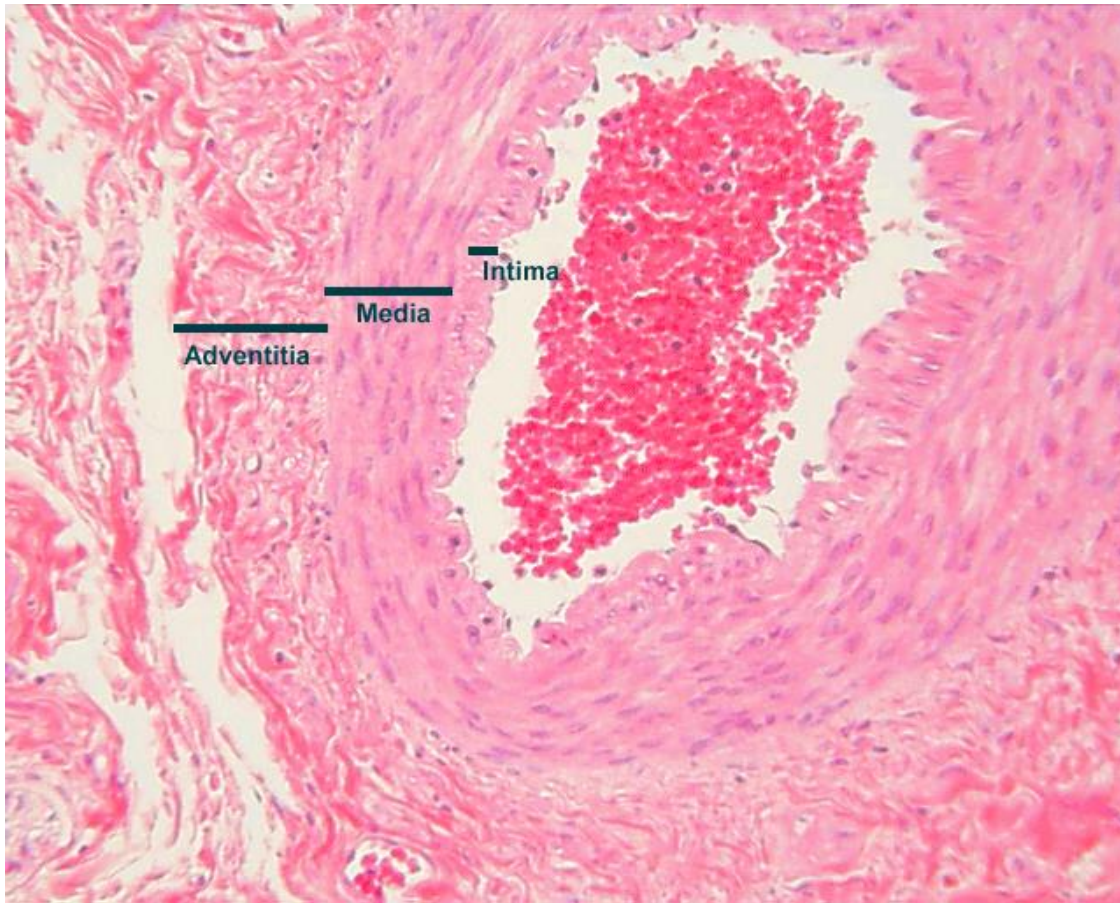
SICKLE CELL ANEMIA





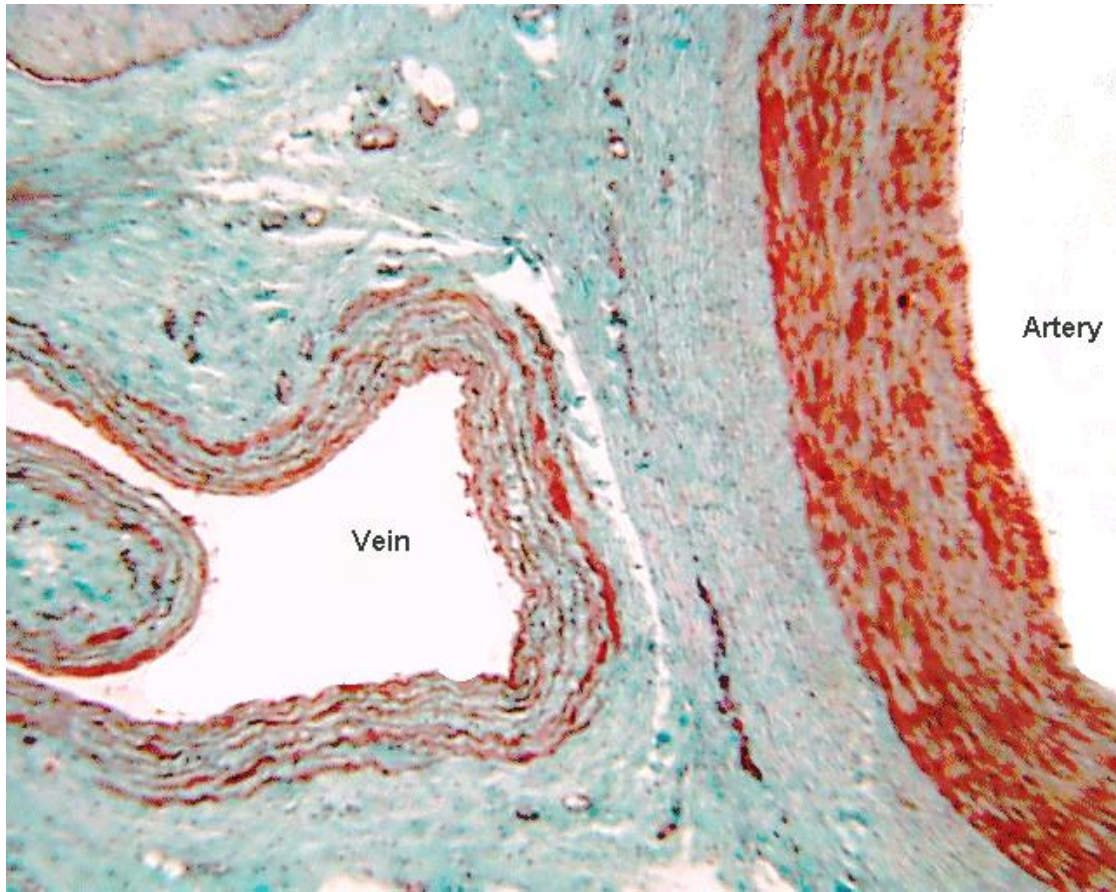
## CROSS SECTION OF ARTERY AND VEIN

### ARTERY





VEIN



ARTERY (TOP PICTURE); VEIN (BOTTOM PICTURE)

