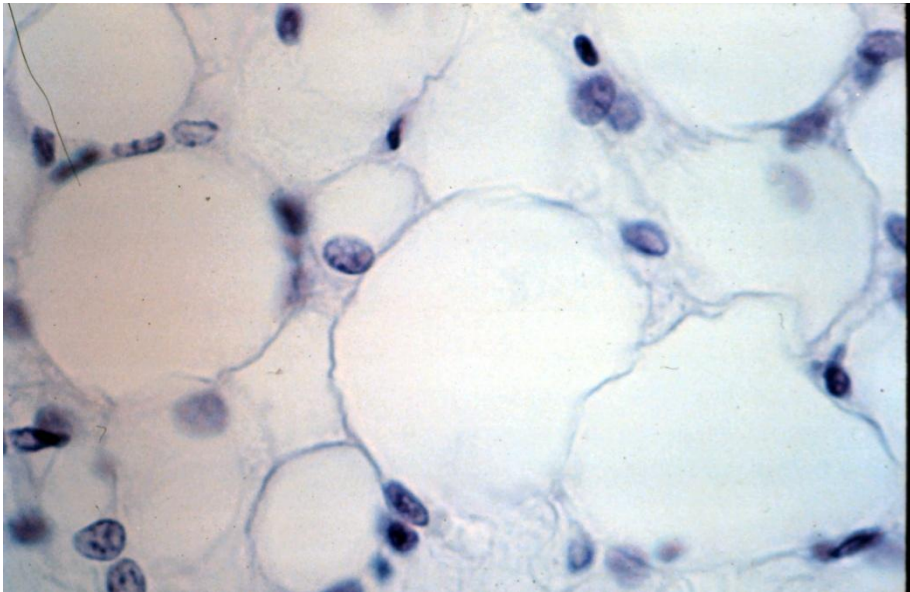
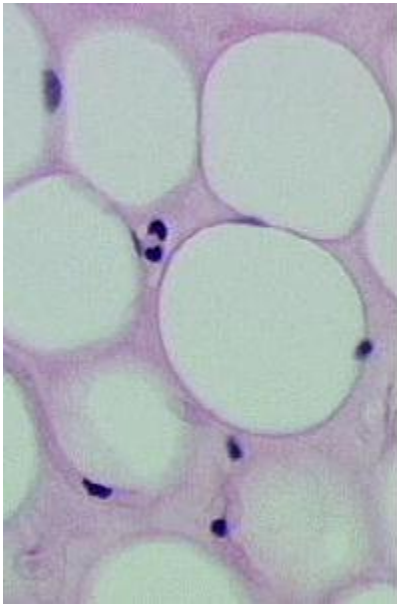


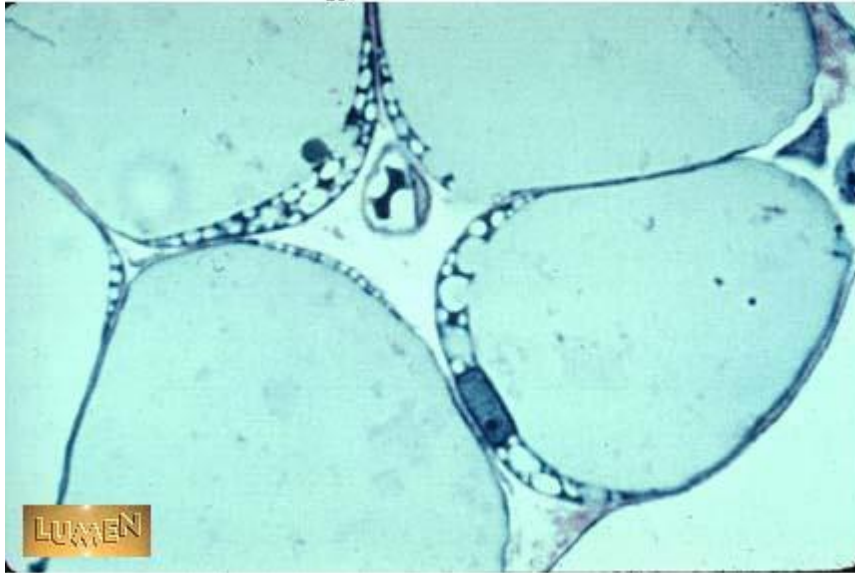Connective Tissue Slides

Adipose

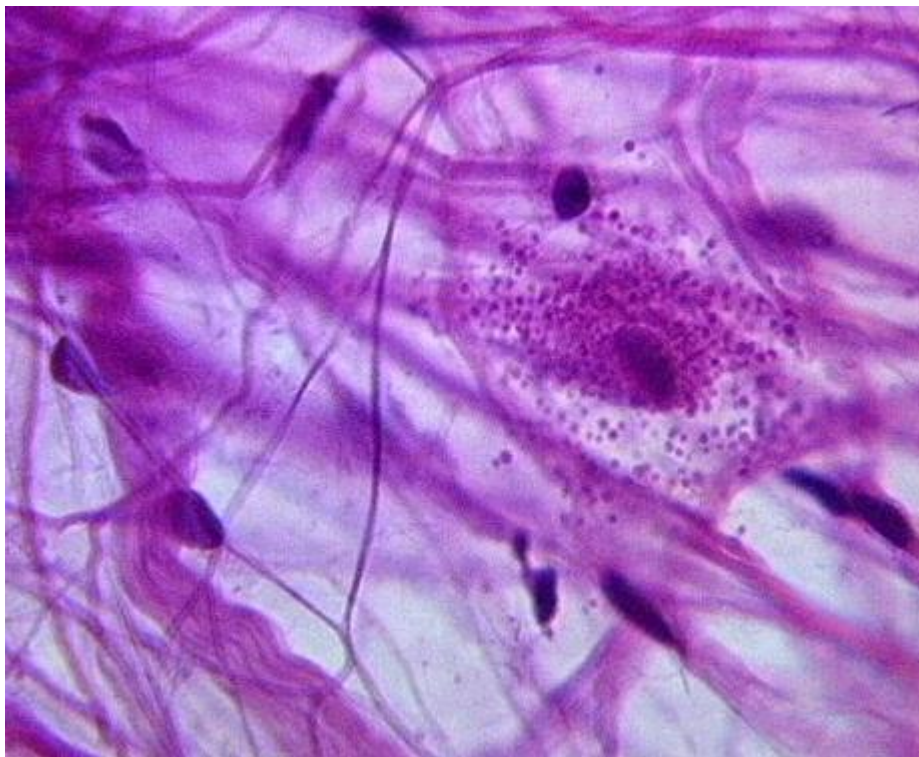


Adipose

Histology Lab Part 3: Slide 11

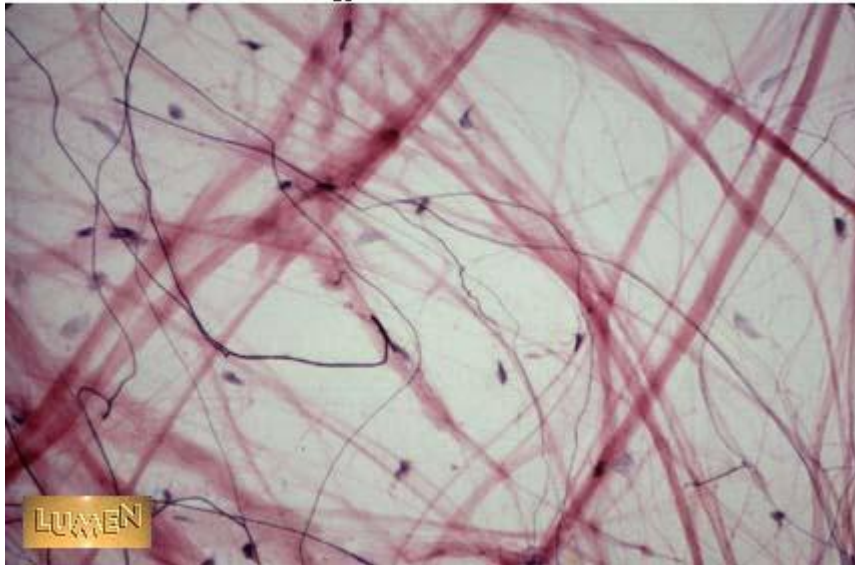


Areolar or Loose Connective Tissue



Areolar or Loose Connective Tissue

Histology Lab Part 3: Slide 8

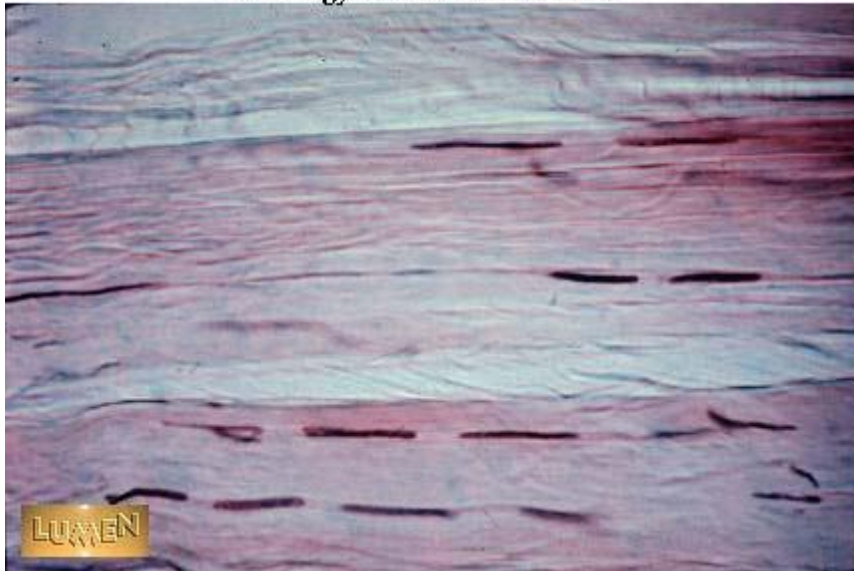


Whit fibrous – Dense Connective Tissue



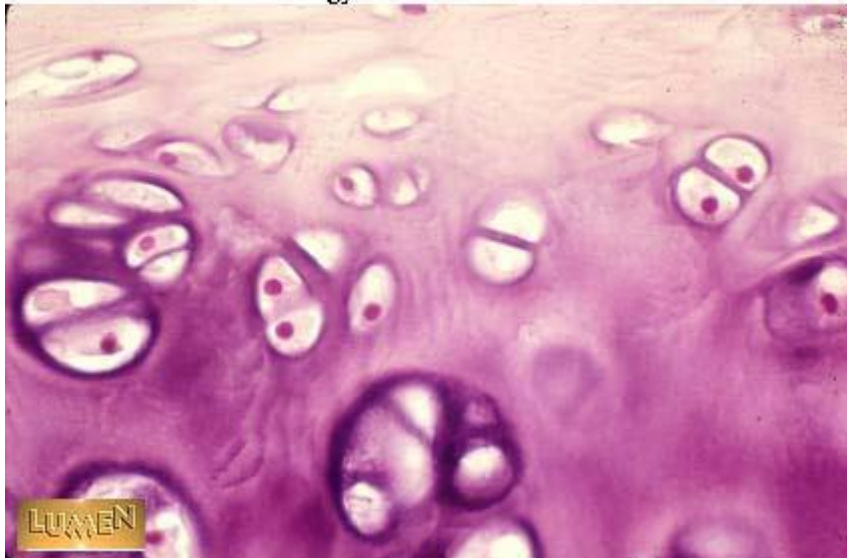
Dense Connective Tissue

Histology Lab Part 3: Slide 15

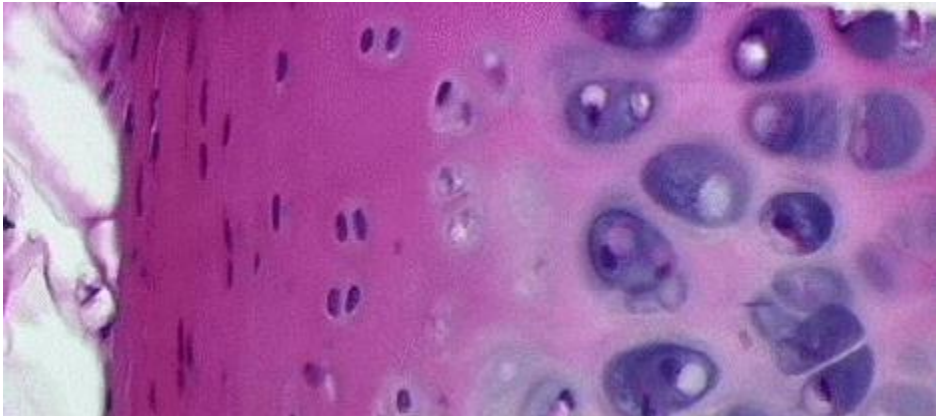


Hyaline Cartilage

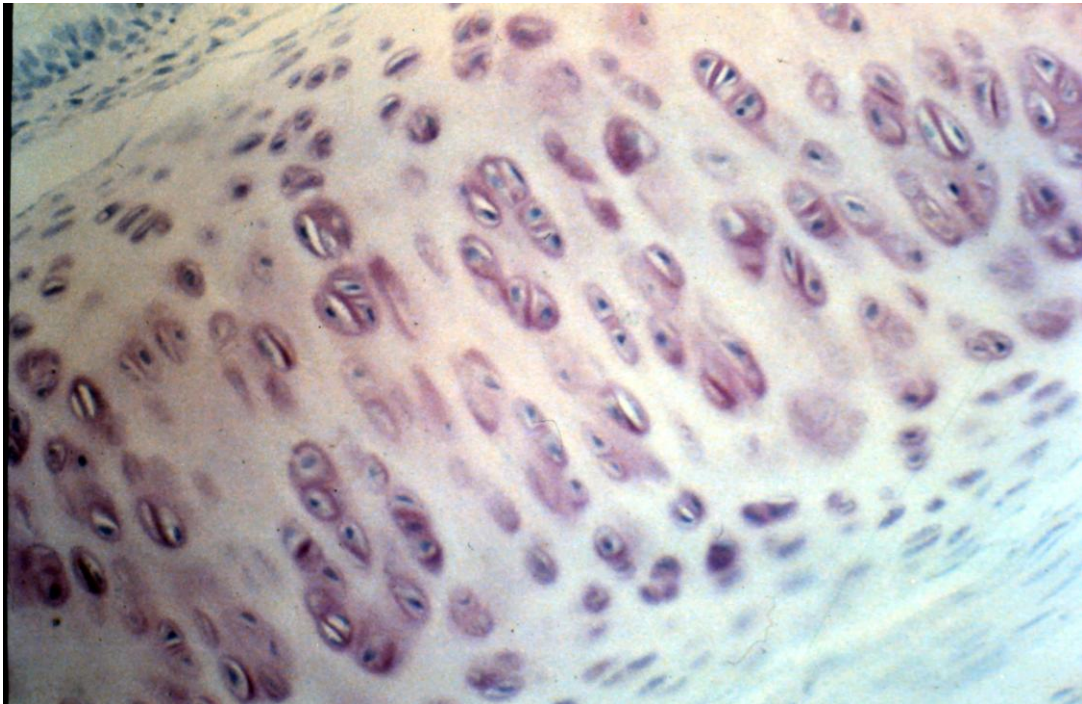
Histology Lab Part 9: Slide 35



Hyaline Cartilage

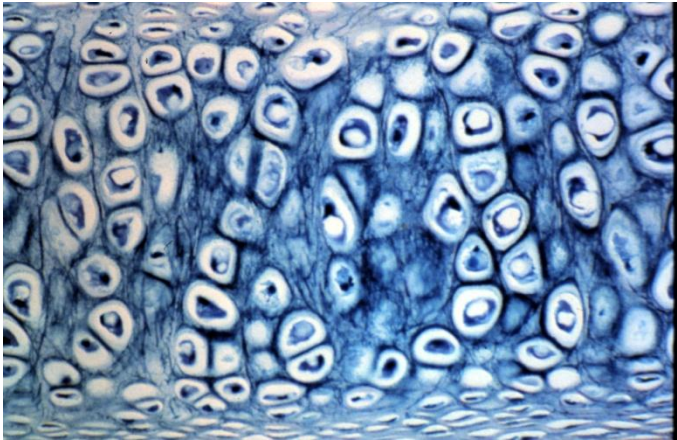
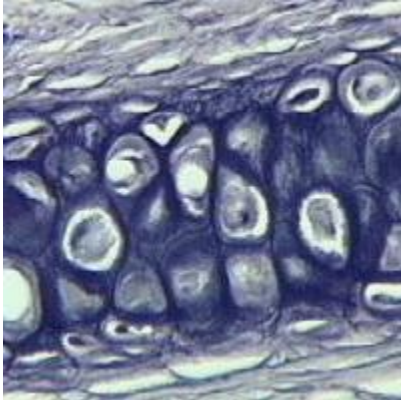
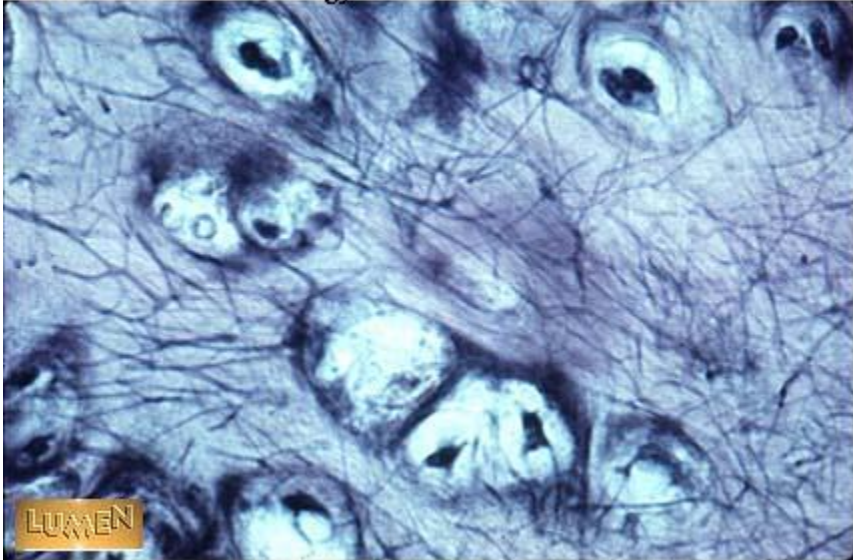


Hyaline Cartilage

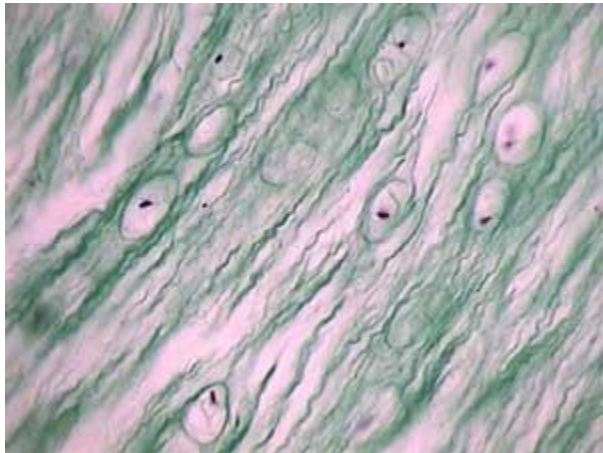
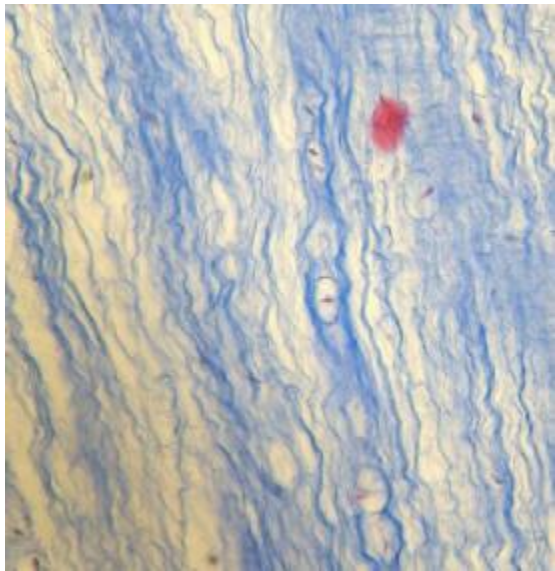


Elastic Cartilage

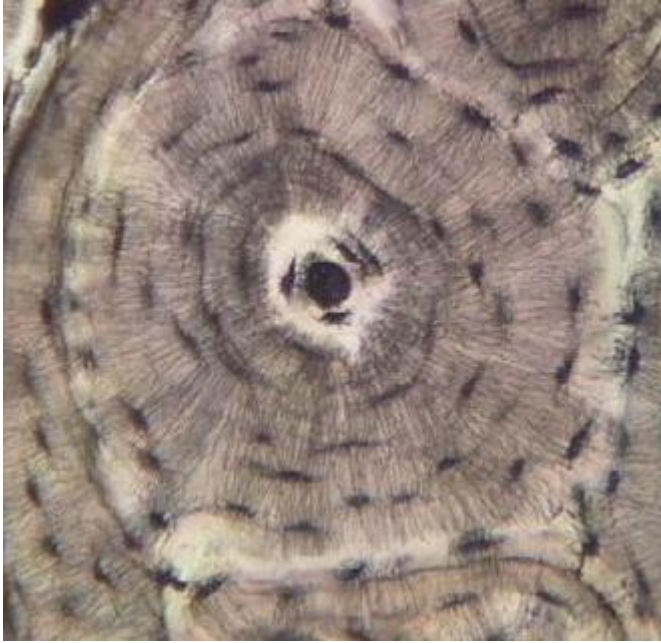Histology Lab Part 9: Slide 36



Fibrocartilage



Compact Bone



Haversian canals

